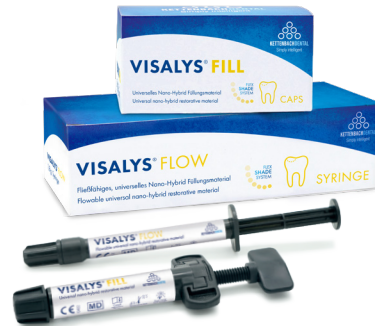

Nano-hybrid composites **Visalys® Fill** and **Visalys® Flow**

Minor esthetic miracles in the daily work of the dental practice

Restorations have long no longer been restricted to simply restoring bite and chewing functions. The advanced esthetic properties of modern filling materials increasingly enable esthetic improvement of an otherwise intact bite or minimally invasive replacement of intact but visually inferior fillings with filling composites whose external appearance is virtually indistinguishable from that of the natural tooth.

This report describes three typical case studies from the everyday practice of esthetic dentistry.



CASE STUDY 1:

A patient (48 years old) presented with a gap between teeth 22 and 23 that she perceived as unattractive (**Fig. 1**). The Vita shade guide was used to select shade A3. After appropriate pre-treatment (roughening with sandblaster, etching with Pep Etch etching gel 36% and Ivoclar Adhese Universal) **Visalys® Flow** was used to widen teeth 22 and 23 (**Fig. 2**) to reduce the gap and achieve a harmonious appearance. The margins were then smoothed with fine diamond finishing, white Arkansas stone and Soflex

disks. **Fig. 3** shows how the teeth were shaped with a foil strip during the application of **Visalys® Flow**.

Fig. 4 demonstrates the situation after polishing. The filling material is harmoniously integrated into the natural tooth substance without visible transitions.

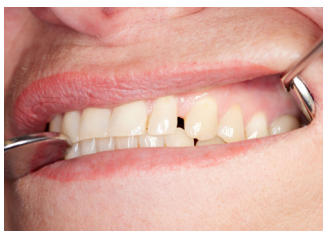

Fig. 1.

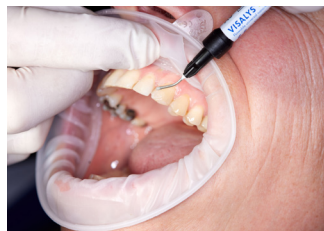

Fig. 2.

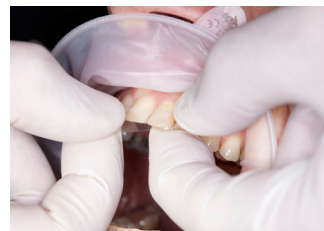

Fig. 3.

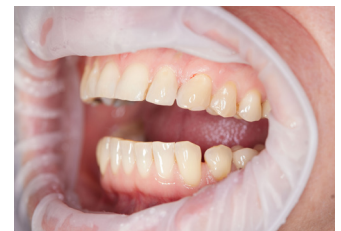

Fig. 4.

CASE STUDY 2:

A young patient (28 years old) with an optimal bite in the maxilla is not satisfied with the shape and size relationship of her top anterior teeth (**Fig. 5**). She feels that the center incisors are too short in comparison and the transition from the top half of the crowns to the gingival margin is too narrow. Tooth 11 also has a slight yellowish discoloration at the incisal margin.

Visalys® Flow was used for adaptation of the tooth shape (**Fig. 6**).

The pre-treatment procedure consisted of roughening the relevant positions with fine diamonds, etching the positions with Pep Etch etching gel 36% and wetting with Adhese Universal Bonding. The stable consistency of the material allows molding

with a PA probe. A smooth incisal margin could be created freehand (**Fig. 7**). The shape of the anterior incisors was carefully harmonized and the yellowish discoloration was removed. The size relationships are improved with the extension of the four incisors (**Fig. 8**). Polishing was conducted with diamond finishers, Arkansas stone and Soflex disks. This detailed, non-invasive treatment has significantly increased the patient's satisfaction with her teeth.

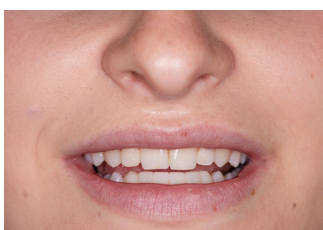

Fig. 5.

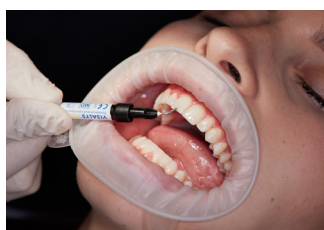

Fig. 6.

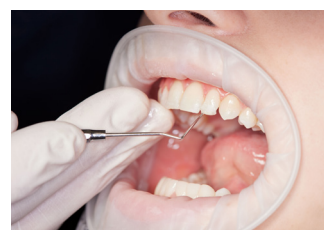

Fig. 7.

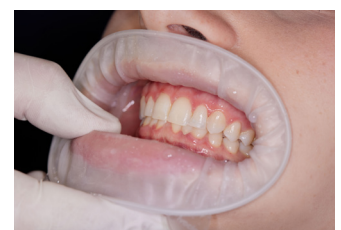

Fig. 8.

Nano-hybrid composites **Visalys® Fill** and **Visalys® Flow**

Minor esthetic miracles in the daily work of the dental practice

CASE STUDY 3:

A woman (52 years old) presented with three amalgam fillings in the third quadrant that she perceived as unattractive (**Fig. 9**) and requested replacement with an esthetic filling composite material. We encounter similar situations comparatively often in the practice and it is up to the dentist to determine whether intact amalgam fillings in the posterior tooth region should be replaced for cosmetic reasons. If there is a risk of leakage in the fillings or if secondary caries is found, this procedure is indicated. However, even if the fillings are intact, the feelings of patients with regard to the unattractive appearance of molars filled with amalgam should be taken seriously.

After removal of the amalgam fillings, the remaining tooth substance proved to be free of caries (**Fig. 10**). A matrix (Tofflemire) was placed in order to shape the MOD fillings correctly, which in this case made a rubber dam unnecessary (**Fig. 10**). After pre-treatment with Pep Etch etching agent and Adhese Universal Bonding the teeth

were structured with filling composite. The patient's natural light tooth shade was best imitated with **Visalys®** shade A1. In order to guarantee an optimum marginal finish the first coating always uses **Visalys® Flow** and then the crown is fabricated with **Visalys® Fill** (**Fig. 11**). This is used because material with very high strength is required in the area subject to high chewing loads. The low stickiness and high stability of the material enabled an anatomically correct structure of the occlusal surfaces and an esthetically satisfactory result (**Fig. 12**).

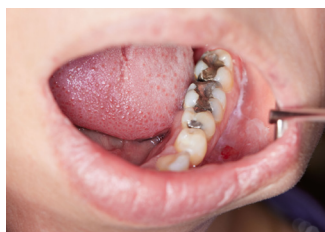

Fig. 9.

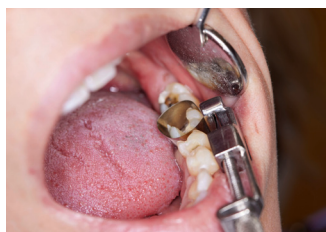


Fig. 10.

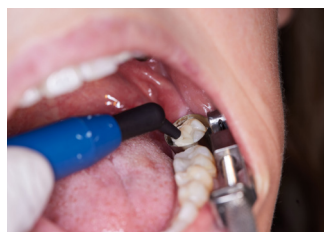

Fig. 11.

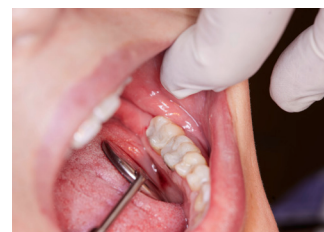

Fig. 12.

CONCLUSION

The goal of esthetic dentistry is always the optimum solution for achieving a dental reconstruction that looks natural, retains as much as possible of the tooth substance and meets the wishes of the patient. A filling material with a smooth consistency and high stability that can be modeled without sticking to the instrument makes the work much easier. These properties enable accurate reconstruction of the original shape of the tooth or can improve the shape of healthy teeth with a suboptimal shape. The ideal situation is a flowable material with good self-leveling properties for an excellent marginal finish combined with good stability that prevents the material from flowing away. At the same time materials that are flowable and can be modeled must also be capable of being polished quickly and reliably to a high gloss and resistant to discoloration combined with good mechanical stability.


Keeping materials in stock is simplified with a filling material with a shade concept that enables one shade to cover several Vita shades.

In this clinical case, the **Visalys®** filling material made it easy to achieve the desired esthetic result because of the extremely user-friendly material properties. The marked chameleon effect ensures that the new filling is harmoniously integrated into the existing dentition. The advantages for the practice are combined with the particularly satisfactory result for the patient for the benefit of both sides.

Dr. Ingo Schröder studied medicine and dentistry at the Philipps University Marburg in the 1970s and received his Dr. med. dent. in 1980.

He has been in practice as a dentist since completing his assistantship in 1982 and is a specialist in esthetic dentistry. He is a member of the German Society for Dentistry, Maxillofacial Surgery and Orthodontics (Deutsche Gesellschaft für Zahn-, Mund- und Kieferheilkunde) and the German Society for Esthetic Dentistry (Deutsche Gesellschaft für ästhetische Zahnheilkunde).

He currently practices in the Wetzlar dental center.



Dr. Ingo Schröder

Dental esthetics • Restorative dentistry • Dentures